

## Diagnostic dilemma in an adolescent with a femoral mass: Osteosarcoma versus pigmented villonodular synovitis.

## Dilema diagnóstico en adolescente con masa femoral: Osteosarcoma frente a sinovitis villonodular pigmentada.

Guzmán Carranza, J. <sup>1</sup> , Pérez Díaz, D. A. <sup>2</sup> , González Salinas, E. G. <sup>3</sup>

<sup>1</sup> Ortopedia y Traumatología. Universidad Autónoma de Sinaloa. ISSSTE Hospital General Dr. Aquiles Calles Rámirez, Servicio de Traumatología y Ortopedia. Calle Dr. Ignacio Cuesta Barrios 33, Colonia Ejido La Cantera. C.P 63506, Tepic, Nayarit, México.

<sup>2</sup> Pediatría. Universidad Autónoma de Nayarit. Hospital Civil de Tepic Dr. Antonio González Guevara, Servicio de Pediatría, Calle Enfermería, Fray Junípero Serra. C.P 63000, Tepic, Nayarit, México.

<sup>3</sup> Traumatología y ortopedia. Universidad Autónoma de Nayarit. Hospital Civil de Tepic Dr. Antonio González Guevara, Servicio de Traumatología y Ortopedia, Calle Enfermería, Fray Junípero Serra. C.P 63000, Tepic, Nayarit, México.



**Please cite this article as/Como citar este artículo:** Guzmán Carranza, J., Pérez Díaz, D. A., González Salinas, E. G. (2025). Diagnostic dilemma in an adolescent with a femoral mass: Osteosarcoma versus pigmented villonodular synovitis. *Revista Bio Ciencias* 12(nesp): Casos clínicos, e1803. <https://doi.org/10.15741/revbio.12.nesp.e1803>

### Article Info/Información del artículo

Received/Recibido: October 29<sup>th</sup> 2024.

Accepted/Aceptado: January 14<sup>th</sup> 2024.

Available on line/Publicado: March 07<sup>th</sup> 2025.

### ABSTRACT

This case involves a 16-year-old male adolescent who presented with intermittent pain in the left knee, worsened by physical activity and accompanied by persistent swelling. Despite initial treatment with analgesics and a splint, symptoms persisted, prompting a magnetic resonance imaging that revealed a soft tissue mass in the distal third of the left thigh, compatible with parosteal osteosarcoma or pigmented villonodular synovitis. Subsequently, a surgical biopsy was performed to confirm the diagnosis. Bone infiltration was observed during the procedure, and the collected samples confirmed malignant osteosarcoma. The patient started chemotherapy under the EURAMOS protocol, achieving a significant tumor reduction of 60%.

This case highlights the importance of a multidisciplinary approach and precise differential diagnosis in young patients presenting with bone masses. The combination of imaging and biopsy was crucial in distinguishing between osteosarcoma and pigmented villonodular synovitis, two entities with very different treatments and prognoses. The case emphasizes the need to suspect malignancy in patients with persistent knee pain and swelling, even when a benign condition is initially considered. Rapid intervention and targeted treatment resulted in a favorable short-term response, underscoring the importance of early detection and management in the prognosis of these tumors. This case provides valuable insights into the management and diagnosis of bone lesions in adolescents.

**KEY WORDS:** Osteosarcoma, Villonodular synovitis, Femoral mass, Adolescent.

### \*Corresponding Author:

**Javier Guzmán Carranza.** Ortopedia y Traumatología. Universidad Autónoma de Sinaloa. ISSSTE Hospital General Dr. Aquiles Calles Rámirez, Servicio de Traumatología y Ortopedia. Calle Dr. Ignacio Cuesta Barrios 33, Colonia Ejido La Cantera. C.P 63506, Tepic, Nayarit, México. Teléfono: (311) 690 1080.

---

## RESUMEN

---

Este caso presenta a un adolescente masculino de 16 años que acudió a consulta por dolor intermitente en la rodilla izquierda, agravado por la actividad física y acompañado de inflamación persistente. A pesar del tratamiento inicial con analgésicos y férula, los síntomas no mejoran, por lo que se realizó una resonancia magnética que reveló una masa de tejidos blandos en el tercio inferior del muslo izquierdo, compatible con osteosarcoma parostal o sinovitis vellonodular pigmentada. Posteriormente, se decidió realizar una biopsia quirúrgica para confirmar el diagnóstico. Durante la cirugía, se observó infiltración ósea, y las muestras obtenidas revelaron osteosarcoma maligno de alto grado. El paciente inició tratamiento quimioterapéutico con el esquema EURAMOS, logrando una reducción tumoral significativa del 60%.

Este caso destaca la importancia de un enfoque multidisciplinario y de un diagnóstico diferencial preciso en pacientes jóvenes con masas óseas. La combinación de métodos de imagen y biopsia fue fundamental para distinguir entre osteosarcoma y sinovitis vellonodular, dos entidades con tratamientos y pronósticos muy distintos. El caso resalta la necesidad de sospechar malignidad en pacientes con gonalgia persistente e inflamación, incluso cuando se considera inicialmente una patología benigna. La rápida intervención y el tratamiento dirigido permitieron una respuesta favorable en el corto plazo, destacando la relevancia de la detección y manejo tempranos en el pronóstico de estos tumores. Este caso aporta experiencia valiosa en el manejo y diagnóstico de lesiones óseas en adolescentes.

---

**PALABRAS CLAVE:** Osteosarcoma, Sinovitis vellonodular, Masa femoral, Adolescente.

---

### Introduction

Bone masses in pediatrics can be either benign or malignant, and their classification is based on histological characteristics and biological behavior. According to the medical literature, bone masses can be categorized into benign, intermediate (locally aggressive or rarely metastatic), and malignant tumors (Bestic, 2020).

### Description and Classification

1. **Benign tumors:** These include osteochondromas, non-ossifying fibromas, enchondromas, and bone cysts. Osteochondromas are the most common benign neoplasms and are usually asymptomatic, although they can cause symptoms due to compression of adjacent

structures. Non-ossifying fibromas are also common and often resolve spontaneously (Tepelenis, 2021; Collier, 2021).

2. **Intermediate tumors:** These include lesions such as giant cell tumors and osteoblastomas, which can be locally aggressive but rarely metastasize (Bestic, 2020).

3. **Malignant tumors:** Osteosarcoma is the most common primary malignant bone tumor in children and adolescents, followed by Ewing's sarcoma. Osteosarcoma is classified as intramedullary, superficial, and extraskeletal, with high-grade intramedullary osteosarcoma being the most frequent (Biermann *et al.*, 2013).

### Tumor Origin Frequency

Most bone masses in pediatrics are benign. A longitudinal study showed that the prevalence of benign bone tumors in asymptomatic children is 18.9 % (Collier, 2021). In contrast, malignant bone tumors are rare, with an estimated incidence of 1 case per 100,000 people per year (Bestic, 2020). In the context of the extremities, malignant tumors such as osteosarcoma represent a minority of cases but are clinically significant due to their potential aggressiveness and need for intensive treatment (Biermann *et al.*, 2013).

Osteosarcoma is the most common primary malignant bone tumor in adolescents, with a peak incidence between 15 and 19 years of age (Biazzo & De Paolis, 2016). It is primarily located in the metaphyseal areas of the distal femur and proximal tibia, corresponding to sites of greatest bone growth. The initial presentation is usually intermittent and localized pain, which is often mistakenly associated with trauma or intense physical activity, thus delaying diagnosis and treatment (Biazzo & De Paolis, 2016; Menendez *et al.*, 2022). Most cases occur in the metaphyseal areas of the distal femur or proximal tibia, which are sites of maximum growth (Biermann *et al.*, 2013). Diagnosis is confirmed through biopsy, and radiological evaluation is crucial for initial diagnosis. Chest computed tomography and positron emission tomography are essential for staging. Treatment generally includes neoadjuvant and adjuvant chemotherapy, along with surgical resection (Biazzo & De Paolis, 2016; Zarghooni *et al.*, 2023).

On the other hand, pigmented villonodular synovitis (PVNS) is not a bone mass; it is a benign proliferative disorder that affects the synovial membrane of the joints, tendon sheaths, or bursae, and is rare in the pediatric population. It is characterized by abnormal growth of synovial tissue, which can be diffuse or localized, and by hemosiderin deposition, giving it its characteristic coloration (Murphey *et al.*, 2008; Hamel-Lemaire & Fortin, 2022; Zhao *et al.*, 2021).

PVNS is more common in the knee, followed by the hip, and may present with pain, swelling, and in some cases, painful hemarthrosis (Murphey *et al.*, 2008; Chipman *et al.*, 2024; Smith & Snyder, 2022).

Diagnosis is primarily made through magnetic resonance imaging (MRI), which shows almost pathognomonic features such as low signal intensity on T2 and the "blooming" artifact due

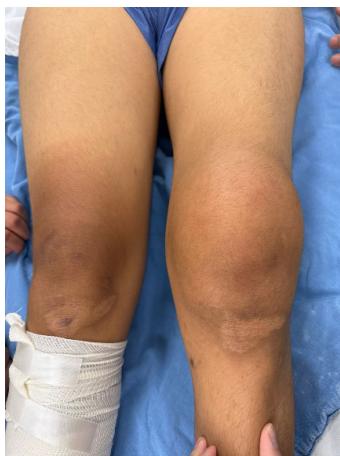
to hemosiderin (Murphey *et al.*, 2008; Meter *et al.*, 2024). The main treatment is synovectomy, which can be open or arthroscopic, although recurrence is common, especially in diffuse disease (Smith & Snyder, 2022; Stevenson *et al.*, 2013; Ramírez-Torres *et al.*, 2024). In some cases, postoperative radiotherapy is considered for local control, especially if positive margins are present (Yang *et al.*, 2019).

The etiology of PVNS is not fully understood, but it has been suggested that it may involve an inflammatory response and cellular proliferation (Zhao *et al.*, 2021). Long-term surveillance is essential to detect recurrences or persistence of the disease (Chipman *et al.*, 2024; Ramírez-Torres *et al.*, 2024).

This case focuses on a 16-year-old male adolescent, residing in Mexico, who presented with left knee pain associated with swelling after playing soccer. The objective is to evaluate the patient's evolution, the diagnostic methods used, and the established treatment, emphasizing the importance of a multidisciplinary approach in pathologies that present similar clinical and radiological characteristics but with very different prognoses and treatments.

## Clinical Case

In February 2024, a 16-year-old male patient began experiencing intermittent knee pain (gonalgia) in his left knee, especially after playing soccer, accompanied by knee swelling (Figure 1). Due to persistent symptoms, he sought medical attention and was initially treated with analgesics and a splint to immobilize the joint. Upon completing treatment and removing the splint, the swelling persisted, prompting his referral to the orthopedic and traumatology department.

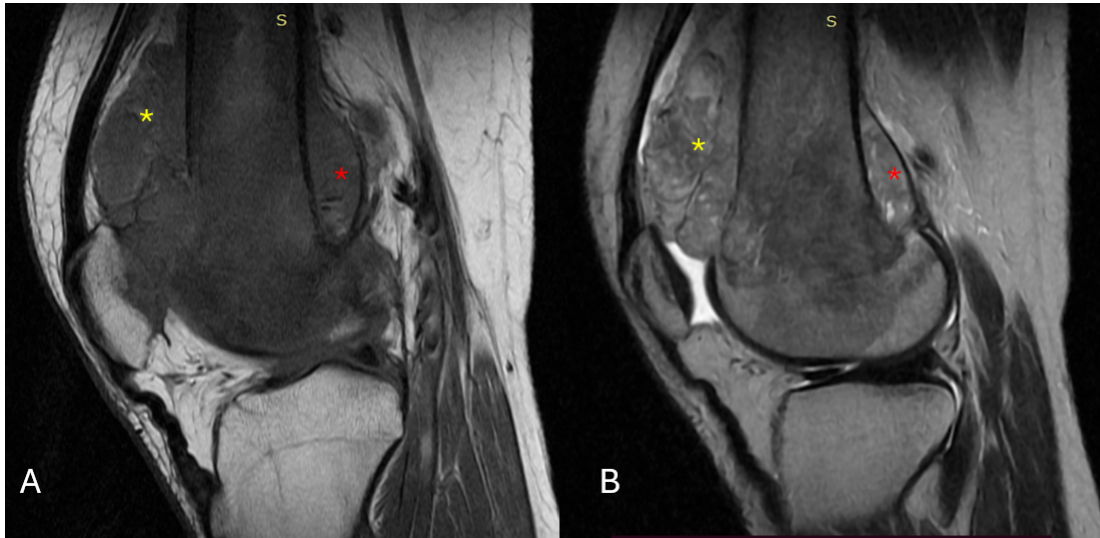


**Figure 1. Photograph of the patient's knees.  
Increase in volume of the left knee compared to the contralateral extremity.**

On April 25, 2024, a MRI scan of the left knee was performed (Figure 2), revealing a soft tissue mass in the distal third of the left thigh, compatible with parosteal osteosarcoma or pigmented villonodular synovitis. Additionally, other abnormalities were observed, such as a grade I injury to the posterior horn of the medial meniscus, an intrasubstance injury of the anterior cruciate ligament, elongation of the patellar ligament, and mild synovial effusion predominantly in the lateral retinaculum.

On May 8, 2024, after a new evaluation in the traumatology department, two possible diagnoses were discussed: osteosarcoma and pigmented villonodular synovitis. Due to diagnostic uncertainty, a surgical resection was scheduled for May 15, 2024, to obtain a biopsy to confirm the diagnosis. It was explained to the patient and his family that if pigmented villonodular synovitis was confirmed, radiotherapy would be indicated, whereas chemotherapy would be initiated if malignancy was confirmed. At that time, the patient was being treated with tramadol and ketorolac, achieving good pain control.

On May 15<sup>th</sup>, 2024, the patient underwent surgery under regional anesthesia. He was positioned in the supine position, and an anterior approach to the left knee was performed with a 12 cm incision. Before initiating the surgical procedure, ischemia of the pelvic limb was applied using an Esmarch bandage to ensure a bloodless surgical field. During the procedure, dissection was performed in layers until the joint was reached, where a medial parapatellar approach was made to access the desired area. Upon observing the synovial tissue, macroscopic features compatible with pigmented villonodular synovitis were noted, prompting the initiation of synovectomy. However, upon reaching the cortex of the lateral condyle, bone infiltration, and cortical lysis were detected, necessitating the collection of both bone and synovial samples for histopathological analysis (Figure 3). The surgery was completed with minimal bleeding of 20 cc, and the total surgical time was 60 minutes. The patient was transferred to the recovery room in good condition, and a compressive dressing was applied.



**Figure 2. Simple magnetic resonance imaging of the left knee.**

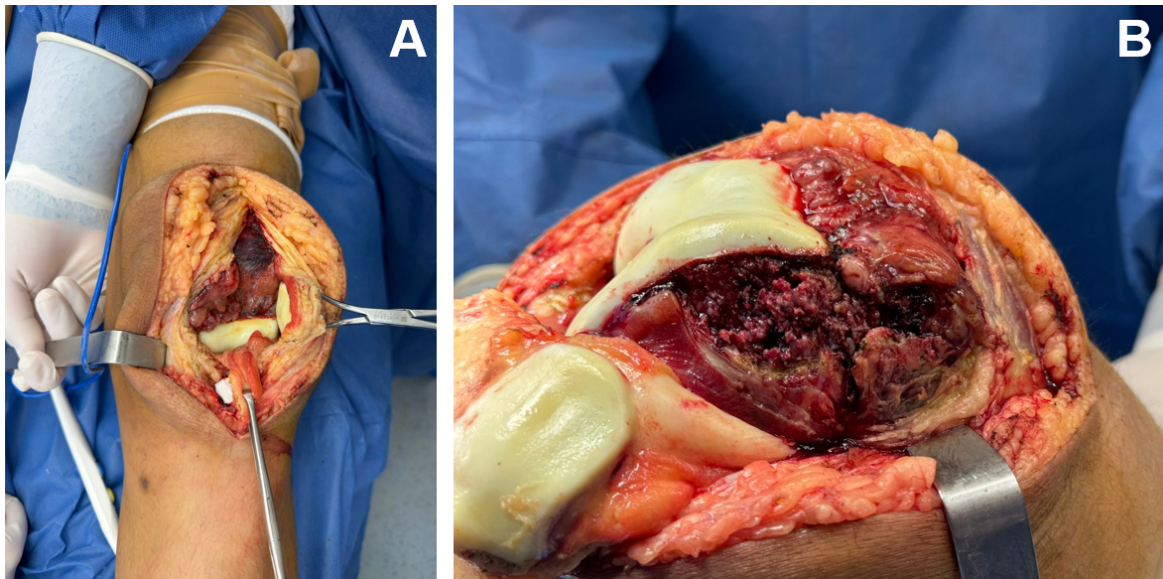
A). Sagittal T1-weighted image of the femoral condyle. B). Sagittal T2-weighted image. A soft tissue mass can be seen in the lower third of the thigh, both in the anterior cortex of the femur (yellow asterisk) and in the posterior cortex (red asterisk). In addition to injury to the posterior horn of the medial meniscus, there is an intrasubstance injury to the anterior cruciate ligament and an elongated patellar ligament, with slight synovial effusion in both retinacula, predominantly on the lateral side.

On June 5, 2024, the biopsy results confirmed the presence of high-grade malignant osteosarcoma in the distal third of the left femur. Following this confirmation, it was decided to initiate chemotherapy under the EURAMOS protocol. The patient was admitted for the first block of neoadjuvant chemotherapy, consisting of Cisplatin (CDDP), Doxorubicin (Adriamycin), and Cardioxane, along with a hyperhydration regimen.

On July 12, 2024, the second cycle of chemotherapy with methotrexate was administered, followed by another admission on July 30 for the second cycle of neoadjuvant chemotherapy under the EURAMOS protocol. Ondansetron, dexamethasone, fosaprepitant, and omeprazole were used as part of the management of side effects. No complications were reported during this cycle.

On August 28, 2024, an evaluation of the patient showed a 60% reduction in tumor size. A third cycle of adjuvant chemotherapy with high doses of methotrexate was administered. On August 31, 2024, folinic acid rescue was initiated to minimize the adverse effects of methotrexate, completing six doses. During treatment monitoring, a urinary pH of 6 was recorded on one occasion, which was corrected with bicarbonate administration without further complications.





**Figure 3. Photographs of tumor resection and biopsy.**

A) A thickened reddish-brown synovial membrane can be observed, compatible with pigmented villonodular synovitis. B). The cortex of the lateral condyle of the left femur, with bone infiltration.

Based on the tumor response and the progress of the treatment, the possibility of performing an amputation is being considered upon completion of the chemotherapy cycles to ensure local disease control and prevent potential recurrences. The evolution of this case highlights the importance of early diagnosis and a multidisciplinary approach in the management of malignant bone tumors in adolescents.

## Discussion

This clinical case demonstrates the importance of a multidisciplinary approach and the use of advanced diagnostic tools for the proper management of bone masses in adolescents, with a particular emphasis on the diagnostic dilemma between osteosarcoma and PVNS. The study results highlight that, in the presence of nonspecific clinical presentations and the possibility of confusion with benign conditions such as PVNS, it is essential to perform an accurate diagnosis through MRI and biopsy to confirm the malignant nature of the lesion. This is consistent with the international literature, which emphasizes the need for early and accurate diagnosis to optimize therapeutic management and improve patient prognosis (Biazzo & De Paolis, 2016; Menendez *et al.*, 2022).

The findings of this case are significant because they illustrate the clinical dilemma involved in managing bone masses with similar clinical presentations. PVNS and osteosarcoma can share

clinical manifestations and radiological findings, underscoring the importance of histopathological confirmation through biopsy as a critical step to avoid diagnostic errors and treatment delays (Murphey *et al.*, 2008). In this regard, MRI showed characteristics compatible with both pathologies, reinforcing the need for a thorough and systematic approach.

Once the diagnosis of osteosarcoma was confirmed, neoadjuvant chemotherapy was implemented, a therapeutic approach aligned with international guidelines and proven to be effective in reducing tumor size, thereby increasing the likelihood of successful and conservative surgical treatment (Zarghooni *et al.*, 2023). This approach, widely documented in the literature, is essential to improving the prognosis and long-term survival of patients with osteosarcoma.

Regarding strengths, the case highlights the correct application of diagnostic and therapeutic protocols, including the use of MRI and biopsy, as well as the administration of evidence-based treatment following clinical guidelines. However, certain inherent limitations of the study must be acknowledged, including the difficulty in generalizing the results due to the reliance on specialized resources available only in referral centers. Additionally, the clinical challenge posed by the similarity between PVNS and osteosarcoma presentations underscores the need to improve access to advanced diagnostic tools in less privileged settings.

In conclusion, this clinical case underscores the diagnostic dilemma in adolescents with a femoral mass, reaffirming the importance of an integral, multidisciplinary, and evidence-based approach to optimize outcomes. Early diagnostic confirmation through biopsy and the timely initiation of appropriate neoadjuvant treatment are key elements that contribute to a better prognosis. These findings provide additional evidence on the efficacy of current treatments and emphasize the need for diagnostic and therapeutic strategies that enable effective and timely management of osteosarcoma.

## Recommendations

**Access to specialized centers:** In contexts where advanced resources for diagnosis and treatment are not available, referral to specialized centers should be considered to ensure a more accurate evaluation and comprehensive treatment as soon as possible.

## Ethical Declarations and Considerations

In this clinical case, written informed consent was not obtained from the patient. To protect privacy and ensure confidentiality, all identifying information about the patient was removed from both the text and the images used in the report. Sensitive data, such as the patient's place of birth, residence, profession, or any other details that could reveal their identity, were excluded.

The clinical case was not experimental and was based on diagnostic and treatment protocols already established in the global medical literature. Evidence-based algorithms were



followed to ensure that management and therapeutic decisions adhered to best clinical practices. Protecting the patient's privacy and confidentiality was a priority at all times, thereby ensuring compliance with ethical principles throughout the preparation of the report.

## Conflicts of Interest and Relevance

The authors declare no conflict of interest.

## References

- Bestic, J. M., Wessell, D. E., Beaman, F. D., Cassidy, R. C., Czuczman, G. J., Demertzis, J. L., Lenchik, L., Motamedi, K., Pierce, J. L., Sharma, A., Sloan, A. E., Than, K., Walker, E. A., Yung, E. Y., & Kransdorf, M. J. (2020). ACR Appropriateness Criteria® primary bone tumors. *Journal of the American College of Radiology*, 17(5S), S226–S238. <https://doi.org/10.1016/j.jacr.2020.01.038>
- Biazzo, A., & De Paolis, M. (2016). Multidisciplinary approach to osteosarcoma. *Acta Orthopaedica Belgica*, 82(4), 690–698. <https://pubmed.ncbi.nlm.nih.gov/29182106>
- Biermann, J. S., Adkins, D. R., Agulnik, M., Benjamin, R. S., Brigman, B. E., Chow, W., Curry, W. T., Frassica, D. A., Frassica, F. J., Jones, R. L., Mayerson, J. L., McGarry, S. V., O'Donnell, R. J., Randall, R. L., Santana, V. M., Satcher, R. L., Siegel, H. J., & Sundar, H. (2013). Bone cancer. *Journal of the National Comprehensive Cancer Network*, 11(6), 688–723. <https://doi.org/10.6004/jnccn.2013.0088>
- Chipman, D. E., Perkins, C. A., Lijesen, E., & Green, D. W. (2024). Pigmented villonodular synovitis/giant cell tumor in the knee. *Current Opinion in Pediatrics*, 36(1), 78–82. <https://doi.org/10.1097/MOP.0000000000001312>
- Collier, C. D., Nelson, G. B., Conry, K. T., & Kormans, J. P. (2021). The natural history of benign bone tumors of the extremities in asymptomatic children: A longitudinal radiographic study. *The Journal of Bone and Joint Surgery. American Volume*, 103(7), 575–580. <https://doi.org/10.2106/JBJS.20.00999>
- Hamel-Lemaire, S., Fortin, M., & Avon, S. L. (2022). Pigmented villonodular synovitis of the temporomandibular joint: Case report and literature review. *Journal of Oral and Maxillofacial Surgery*, 80(10), 1691–1704. <https://doi.org/10.1016/j.joms.2022.07.001>
- Menendez, N., Epelman, M., Shao, L., Douglas, D., & Meyers, A. B. (2022). Pediatric osteosarcoma: Pearls and pitfalls. *Seminars in Ultrasound, CT, and MR*, 43(1), 97–114. <https://doi.org/10.1053/j.sult.2021.05.010>
- Meter, J., Anthony, T., Wingender, H., & Smith, S. (2024). Pigmented villonodular synovitis of the flexor hallucis longus tendon: A rare cause of leg pain in a 12-year-old girl. *Radiology Case Reports*, 19(4), 1258–1262. <https://doi.org/10.1016/j.radcr.2023.12.053>
- Murphey, M. D., Rhee, J. H., Lewis, R. B., Fanburg-Smith, J. C., Flemming, D. J., & Walker, E. A. (2008). Pigmented villonodular synovitis: Radiologic-pathologic correlation. *RadioGraphics*, 28(5), 1493–1518. <https://doi.org/10.1148/rq.285085134>
- Ramírez-Torres, A. A., Hernández-Contreras, M., Almela-Mendoza, R. A., Muñoz-Cabello, R.

- A., Aguilar-Orduño, E. J., & Hernández-Aragón, F. (2024). Open surgical management of recurrent pigmented villonodular synovitis: Case report and literature review. *Acta Ortopédica Mexicana*, 38(4), 263–266. <https://doi.org/10.35366/116313>
- Smith, S. C., & Snyder, G. M. (2022). Orthopedic management of a patient with pigmented villonodular synovitis. *JAAPA: Official Journal of the American Academy of Physician Assistants*, 35(11), 1–4. <https://doi.org/10.1097/01.JAA.0000885160.53208.1d>
- Stevenson, J. D., Jaiswal, A., Gregory, J. J., Mangham, D. C., Cribb, G. L., & Cool, P. (2013). Diffuse pigmented villonodular synovitis (diffuse-type giant cell tumour) of the foot and ankle. *The Bone & Joint Journal*, 95-B(3), 384–390. <https://doi.org/10.1302/0301-620X.95B3.30192>
- Tepelenis, K., Papathanakos, G., Kitsouli, A., Vlachos, K., Barbouti, A., & Kanavaros, P. (2021). Osteochondromas: An updated review of epidemiology, pathogenesis, clinical presentation, radiological features and treatment options. *In Vivo*, 35(2), 681–691. <https://doi.org/10.21873/invivo.12308>
- Yang, X., Sun, Y., Yu, W., & Fu, J. (2019). Pigmented villonodular synovitis of the temporomandibular joint: Case report and the literature review for postoperative radiotherapy. *Journal of Radiology Case Reports*, 13(8), 31–39. <https://doi.org/10.3941/jrcr.v13i8.3661>
- Zarghooni, K., Bratke, G., Landgraf, P., & Kopp, M. (2023). The diagnosis and treatment of osteosarcoma and Ewing's sarcoma in children and adolescents. *Deutsches Arzteblatt International*, 120(24), 405–412. <https://doi.org/10.3238/arztebl.m2023.0079>
- Zhao, Y., Lv, J., Zhang, H., & Wei, Y. (2021). Gene expression profiles analyzed using integrating RNA sequencing, and microarray reveals increased inflammatory response, proliferation, and osteoclastogenesis in pigmented villonodular synovitis. *Frontiers in Immunology*, 12, 665442. <https://doi.org/10.3389/fimmu.2021.665442>